

FRONTAL LOBE

HIPPOCAMPUS



## 12.5 Cognitive, Social, and Emotional Effects of Prefrontal Cortex Lesions

The large area of the frontal cortex anterior to the primary and secondary motor cortex is the *prefrontal cortex*. Although the prefrontal cortex has often been assumed to be the seat of intelligence, large prefrontal lesions have little or no adverse effect on the ability to perform conventional tests of intelligence. However, appropriately designed tests reveal several major deficits, which depend to a large degree on the particular area of the prefrontal cortex that has been damaged.

The prefrontal cortex contains three large areas: the **dorsolateral prefrontal cortex**, which is on the lateral surface of the prefrontal cortex just in front of the *premotor cortex*, the **orbitofrontal cortex**, which is on the *frontal pole* (i.e., on the anterior tip of the brain) and inferior surface of the prefrontal lobes just next to the orbits (i.e., eye sockets), and the **medial prefrontal cortex**, which includes anterior portions of the *cingulate gyrus*.

Damage to the dorsolateral cortex often results in deficits in creative thinking, in remembering the temporal sequence of events but not the events themselves, in inhibiting incorrect but previously correct responses, and in developing and following plans of action. Damage to the orbitofrontal cortex often results in marked personality changes, particularly in the ability to inhibit inappropriate behaviors consistently behave in socially acceptable ways. Damage to the medial prefrontal cortex often results in emotional blunting; patients with damage to medial prefrontal cortex react only slightly to positive or negative emotion-inducing events that induce extreme positive or negative emotions in most people.

### **Dorsolateral prefrontal cortex**

The large area on the lateral surface of the prefrontal lobes, which plays a role in memory for temporal order, response sequencing, response inhibition, and creative thinking.

### **Orbitofrontal cortex**

The large area of prefrontal cortex on its anterior pole and inferior surface; lesions of this area often lead to inappropriate social behaviors.

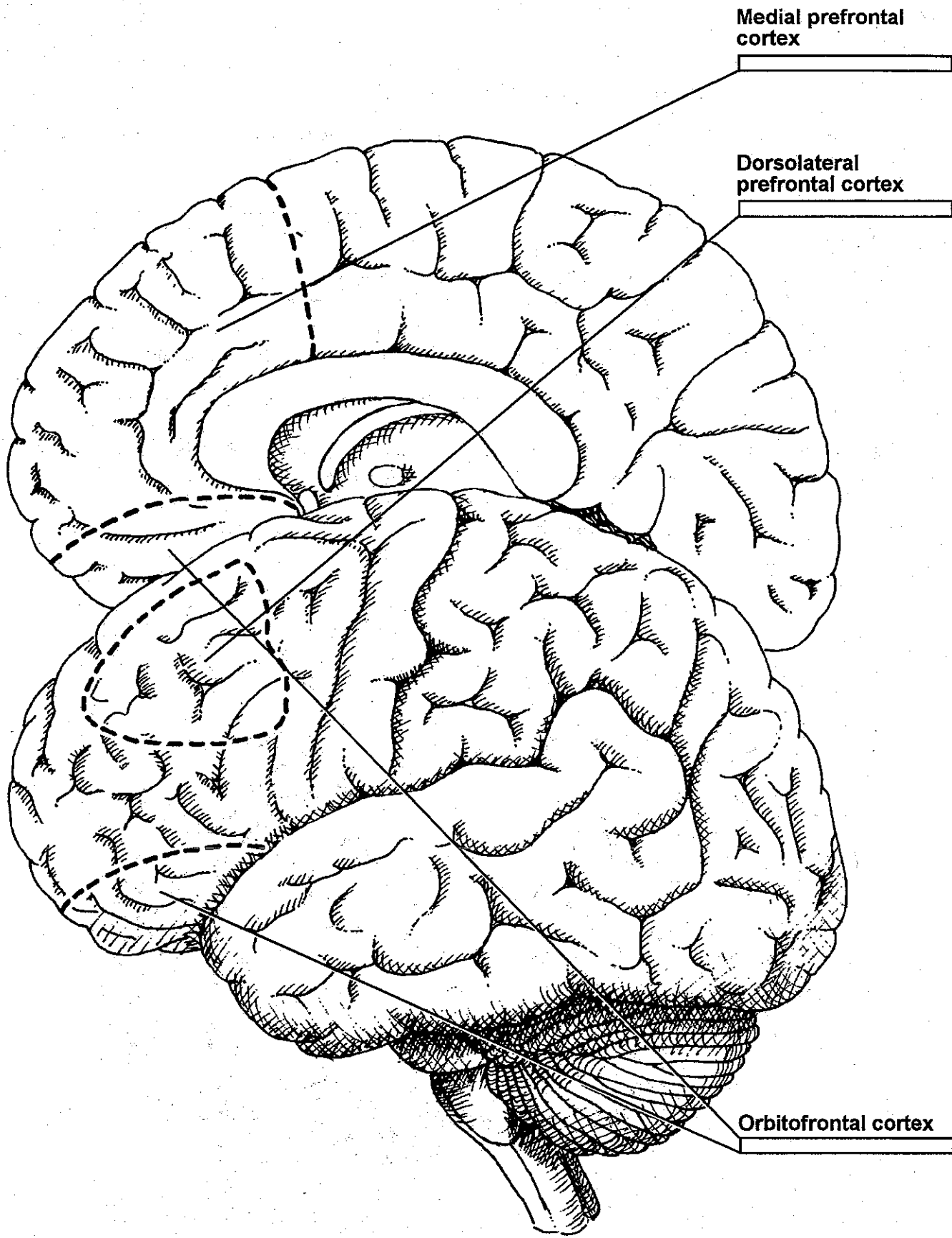
### **Medial prefrontal cortex**

The area of prefrontal cortex on the medial surface of the prefrontal lobes; lesions to this area produce a blunting of affect.

---

### **Coloring notes**

First, color the orbitofrontal cortex shown in both the top (medial orbitofrontal) and bottom (lateral orbitofrontal) illustrations. Then, color the medial prefrontal cortex in the top illustration and the dorsolateral prefrontal cortex in the bottom.



Medial prefrontal cortex

Dorsolateral prefrontal cortex

Orbitofrontal cortex

## 10.1 Hippocampal Formation and Memory: The Case of H.M.

In the early 1950s, H.M. had the medial portions of both his temporal lobes removed in an effort to control a life-threatening case of epilepsy. This *medial temporal lobectomy* greatly improved H.M.'s health, but it left him with a severe case of amnesia.

Since his surgery, H.M. has been incapable of forming new long-term *explicit memories*, long-term memories of which he has conscious awareness. In contrast, he has only mild amnesia for experiences that occurred before his surgery; he has a normal *short-term memory* (i.e., he can remember things for brief periods while he concentrates on them); and he has normal *implicit memory* (i.e., he can demonstrate retention of information by improved performance although he has no conscious awareness of the information). If you met H.M., he could chat with you quite normally until his attention was distracted, at which point he would have no recollection of you or your conversation.

H.M.'s case suggests that one or more of the structures of the medial temporal lobes plays a role in converting short-term memories into long-term memories—a process known as *memory consolidation*. Although several major structures are damaged by medial temporal lobectomy—which you may have surmised is no longer used as a treatment for epilepsy—it was initially assumed that H.M.'s memory deficit resulted from damage to his **hippocampal formation**. The **hippocampal formation** is composed of three cortical structures: the **hippocampus**, the **dentate gyrus**, and the **subicular cortex** (or **subiculum**). The hippocampus and dentate gyrus are *allocortex*; subicular cortex is part of a transitional area between the hippocampus and neocortex.

Many axons that project from the hippocampus run along its medial surface in a bundle called the **fimbria**. The axons of the fimbria project into the *fornix*.

### Hippocampal formation

The medial temporal lobe structure that is composed of the hippocampus, dentate gyrus, and subicular cortex; also referred to as the *hippocampal complex*.

### Hippocampus

The large fold of medial temporal lobe allocortex that is located between the edge of the cortical mantle and the subicular cortex; its structure in cross section reminded early neuroanatomists of a seahorse (*hippocampus* means *seahorse*).

### Dentate gyrus

The allocortical gyrus in the medial temporal lobe; in cross section, it is a C-shaped structure that curves around the edge of the hippocampus.

### Subicular cortex (sub IK yu lar)

An area of transitional cortex adjacent to the hippocampus; subicular cortex is folded like a supporting platform beneath the hippocampus and dentate gyrus (*subicular* means *supporting*).

### Fimbria

A bundle of axons that courses along the medial surface of the hippocampus; it carries signals from the hippocampus to the fornix.

### Coloring notes

First, color the position of the hippocampal formation in the upper illustration—note that the hippocampal formation would not be visible from this lateral view because it is a medial structure. Then, color the components of the hippocampal formation: the hippocampus, the dentate gyrus, and the subicular cortex. Finally, color the fimbria.

